UK & Ireland Prostate Brachytherapy Users Group: Physics (technology) Update

William Keough
Head of Brachytherapy
Consultant Clinical Scientist
Edinburgh Cancer Centre
Western General Hospital

SEDASYS – The Machine That Could Replace Anaesthesiologists

- It can only be used for simple procedures for now, but that's changing
- Sedasys anaesthesiology machine to sedate patients before surgery. Johnson & Johnson has been “cautiously” rolling out the machine after winning approval from the Food and Drug Administration in 2013.
- NOTE: no CE mark to date!

A Fully Actuated Robotic Assistant for MRI-Guided Prostate Biopsy and LDR Brachytherapy procedures



Areas of clinical interest from a Physics perspective

1. Improving Implant Dosimetry
2. Functional Imaging – Improved Targeting For Focal Implants

Effect of Prostatic Calcifications on dosimetry in I-125 Brachytherapy

Brad Oborn[1,2] Stacy Miller[3], Joe Bucci[3]
[1]Illawarra Cancer Care Centre, Wollongong Hospital
[2]Centre for Medical Radiation Physics, University of Wollongong
[3] St George Cancer Care Centre, Kogarah NSW

Methods Used

1. Monte Carlo simulations were performed using the Geant V. 4.9.3 software with Matlab.
2. Voxelized phantom from the CT scan
3. Removed Voxels to eliminate interseed attenuation
4. Identified Voxels with calcium attenuation properties
5. I-125 seed specifications from the manufacturer measured energy spectrum
6. 3 patients were examined to simulate the effects of calcium attenuation on the dosimetry

Patient #1

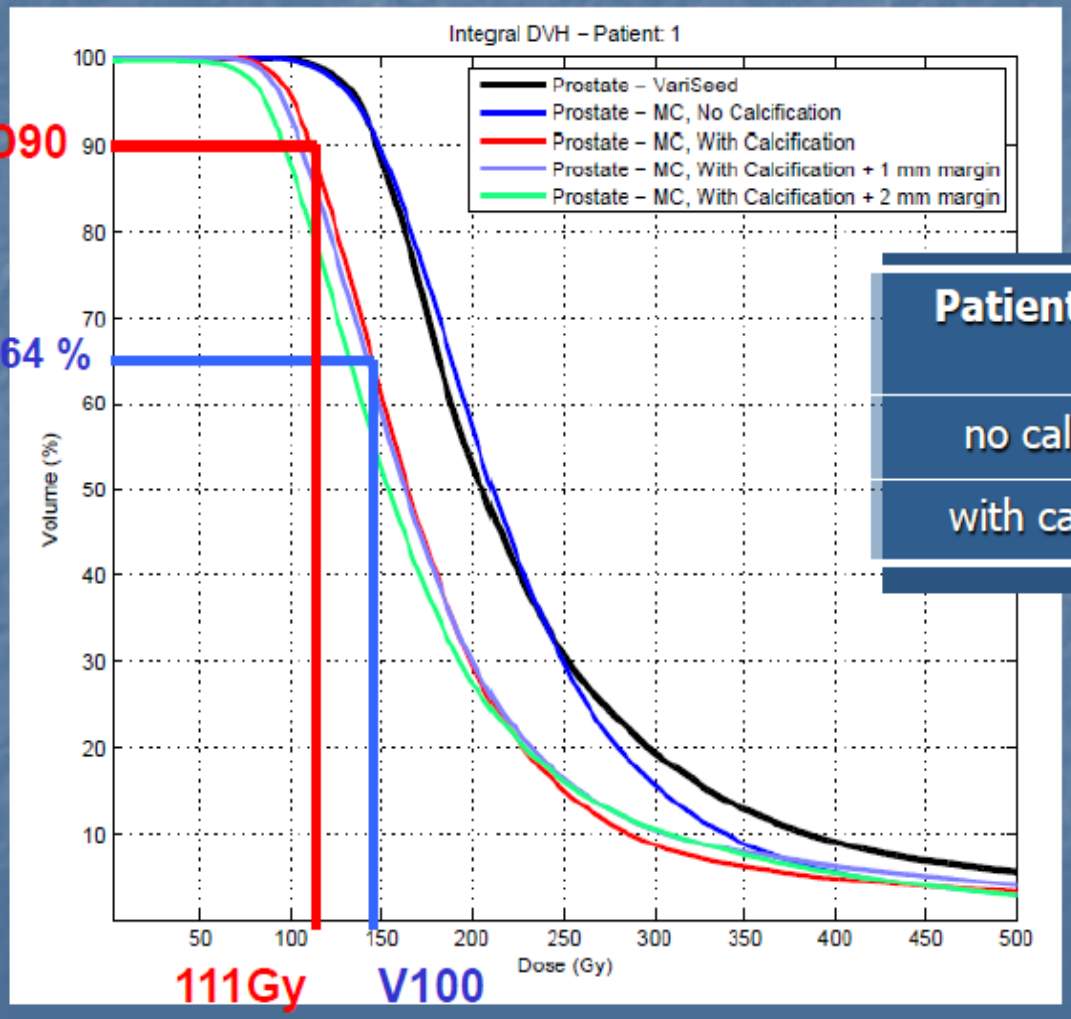

Patient 1	V100 (%)	D90 (Gy)
no calc	91.2	149
with calc	64.3	111

V100 Goal:
>90: good
>80: fair
<80: poor

D90 Goal:130-180Gy

Patient #1

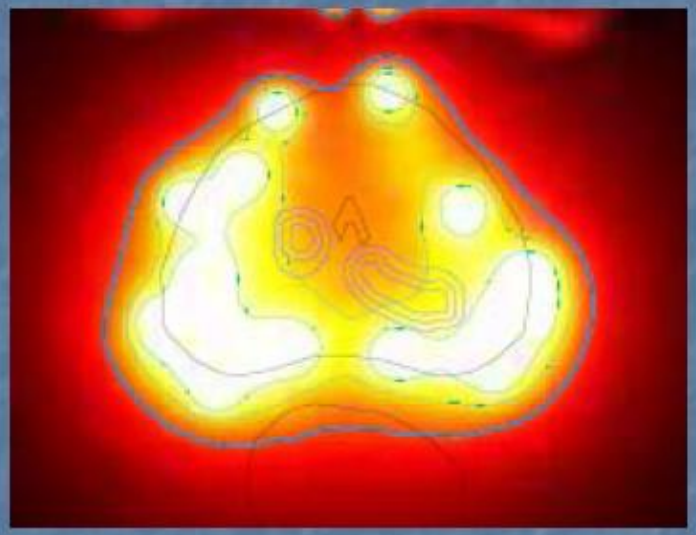

No Calcification

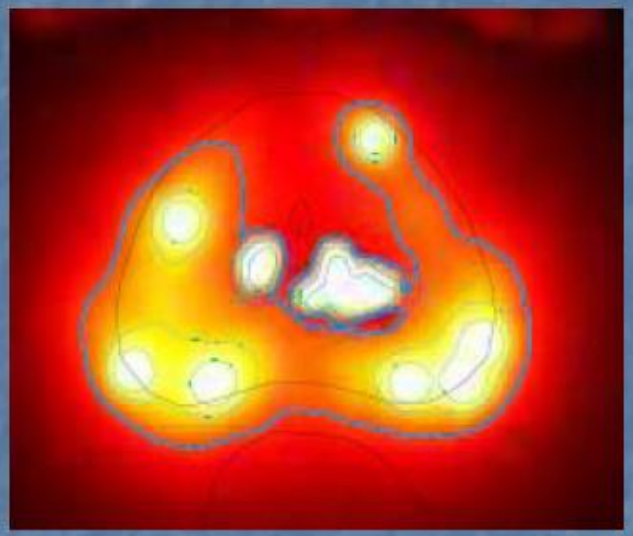

With Calcification

V100 and D90 values corrected for Calcium Attenuation

Patient #	V100 Normal %	V100 Calcium %	D90 Normal (Gy)	D90 Calcium (Gy)	Prostate Volume (cc)
1	91.2	64.3	149	111	51.2
2	99.4	65.8	211	110	28.6
3	94.2	89.4	159	145	38.1

Conclusions

- Monte Carlo Simulations are only as accurate as the source model and materials defined
- These results indicate clinically significant differences due to calcium attenuation
- This simulation should correct not only for calcium but interseed attenuation which can be significant in LDR salvage patients
- It would be desirable to identify patients that would benefit from a pre-implant simulation

Focal Therapy (FT)

- Delphi Consensus Project goal to reach standardized terminology in focal therapy for prostate cancer[1].
- Advantages of using Focal Therapy:
- Monotherapy to spare dose to the entire prostate and possible reduce side effects to the organs at risk.
- Boost therapy in combination with EBRT
- Salvage therapy after EBRT or Brachytherapy recurrence.

1. Standardization of definitions in focal therapy of prostate cancer: report from a Delphi consensus project, A.W. Postema et al, World J. Urology, online publication 18/2/2016.

Focal Therapy: Identifying the cancer

I. **Functional Imaging techniques**:

1. Choline PET CT imaging using F^{18}-fluorocholine which has a longer half life (110 min) than C^{11}-Choline (20 min) but has the disadvantage of being excreted in urine so early imaging is critical.
2. Multiparametric MRI Using T2 images with one or more functional studies (Diffusion weighted MRI or Dynamic Contrast-enhanced MRI).

II. **Image guided biopsy** :

1. Ultrasound or MRI guided transperineal template-guided mapping biopsies

Treatment Planning Focal Therapy

- Target identification: functional imaging and biopsy information
- Margins: (GTV + margin) = Clinical Target Volume (CTV)
- Dose – “standard” 145 Gy for LDR,
- 19”+” Gy for single fraction HDR
- V100 and D90 dose targets(?)
- Dosimetric planning objectives: Bladder, Urethra, Rectum, Penile bulb

Success and Failure in Focal Therapy

- **The Delphi Consensus Project identified three reasons for failure of focal therapy:**
- Ablation Failure: failure to destroy the tissue within the intended treated zone multiparametric MRI imaging is suitable for monitoring this.
- Targeting Failure: when the ablative energy is not correctly applied to the tumour spatially.
- Selection Failure: inappropriate patient selection. Short term post treatment identification of metastatic or locally advanced disease.

Conclusions

- Focal Therapy is gaining interest as a alternative to treating the whole prostate
- Significant dose reductions to previously treated organs at risk are possible when treating recurrent disease
- Identification of the treatment volume (CTV) will be challenging as margins around the functional imaging target may vary depending on the procedures used
- Focal Therapy allows more flexibility in planning and treating the CTV when compared to treating the whole prostate